



Review Article

Value of Ultrasound in Evaluation of Abnormal Axillary Lymph Node

Abdelmohsen Radwan Hussien¹, Monaliza El-Quadi², Avicce Oconnell³

¹Department of Radiology, SUNY Upstate Medical University, Syracuse, ²Medical Consultation and Research, Jamesville, ³Department of Radiology, URMC, University of Rochester, New York, United States.



***Corresponding author:**

Abdelmohsen Radwan Hussien,
Department of Radiology,
SUNY Upstate Medical
University, 750 E Adams St,
Syracuse - 13210, New York,
United States.

mohsen104@yahoo.com

Received : 12 June 2020

Accepted : 06 April 2021

Published : 29 September 2021

DOI

10.25259/AJS_3_2020

Quick Response Code:



ABSTRACT

Understanding of the various appearances of axillary lymph nodes (LNs) is essential for diagnosing and planning of breast cancer treatment. In this article, the role of ultrasound in detecting abnormal appearing metastatic LNs is discussed, with emphasis on most of the ultrasonographic features and tools which might help improve detection of axillary LN pathology.

Keywords: Angular margin, Cortical/hilum ratio, Longitudinal/transverse ratio, Perinodal invasion, Sonoelastography

INTRODUCTION

Detection of suspicious axillary lymph nodes (LNs) is important in breast cancer diagnosis, staging, treatment, prognosis, and follow-up. Ultrasound evaluation of axillary LNs is now a routine practice in many imaging centers, especially when the breast primary cancer is large. Although ultrasound plays an important role in detection of LN metastatic disease, many involved LNs may still be missed. It is known that overall size and shape are a relatively poor criterion for evaluation of metastasis; cortical thickness and asymmetry are more significant. The subtle sonographic signs for detecting metastatic LNs are important to know.

NORMAL SONOGRAPHIC APPEARANCE OF AXILLARY LNS

A benign LN is ovoid, with a hypoechoic cortex, thin or even invisible at ultrasonography with a hyperechoic hilum due to connective tissue trabeculae, lymphatic tissue cords, and medullary sinusoids.^[1] Smooth thin outer echogenic cortex measuring <4 mm is a sign of a normal LN [Figures 1, 2a-c and 3].

BILATERAL AXILLARY ENLARGED LNS

Bilateral enlarged LNs are seen in many autoimmune diseases, for example, Rheumatoid arthritis, systemic lupus erythematosus, psoriasis, scleroderma, and dermatomyositis. They can also be seen in lymphoid hyperplasia from acute or chronic infection/inflammation, such as infectious mononucleosis and cat scratch disease, granulomatous disease such as diabetic mastopathy, sarcoidosis, tuberculosis, and silicone-induced granulomatous adenitis.^[2-4] In addition, bilateral

This is an open-access article distributed under the terms of the Creative Commons Attribution-Non Commercial-Share Alike 4.0 License, which allows others to remix, tweak, and build upon the work non-commercially, as long as the author is credited and the new creations are licensed under the identical terms.

©2021 Published by Scientific Scholar on behalf of American Journal of Sonography

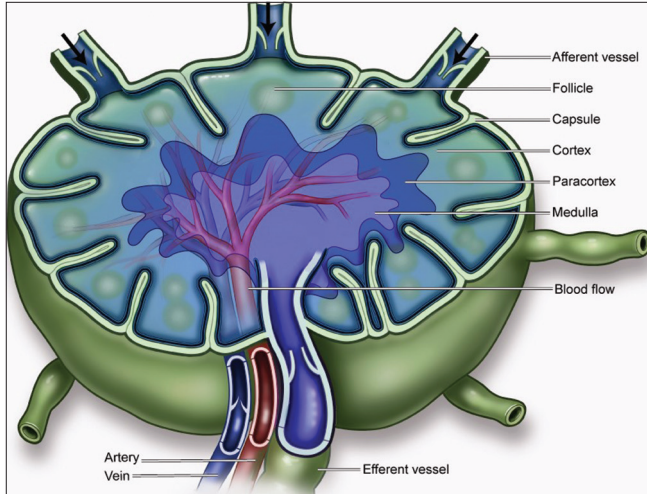


Figure 1: An illustration of the normal anatomy of the lymph node (LN), showing the hilum, afferent and efferent vessels, capsule, follicle, cortex, medulla, artery, and vein. Metastatic cells in the lymph reach the LNs through afferent lymphatic vessels located in the convex side of the LN.

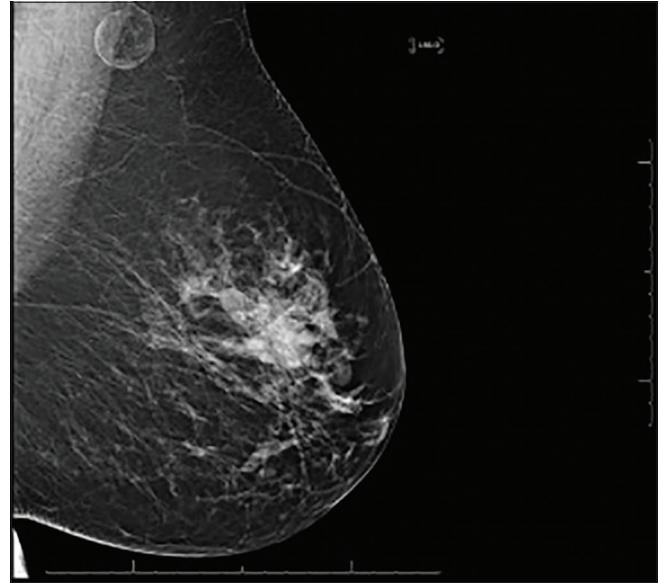


Figure 2c: Mammographic correlate to the LN of Figure 2b.

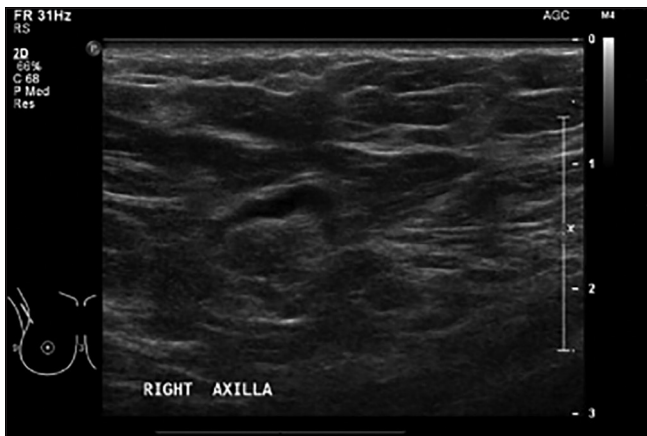


Figure 2a: A 55-year-old male who presents with right retroareolar pain. LN with normal cortical thickness. 3 mm is usually considered normal.

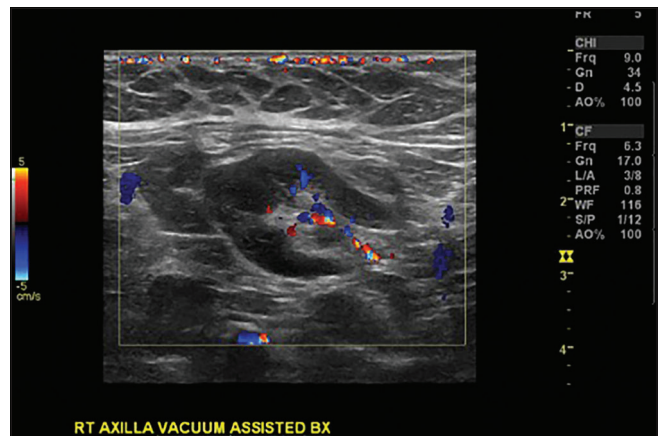


Figure 3: A 54-year-old female with history of breast cancer. Biopsy proven benign reactive (lymph node) LN. Enlarged LN with uniform cortical thickening with no transcortical vessels.

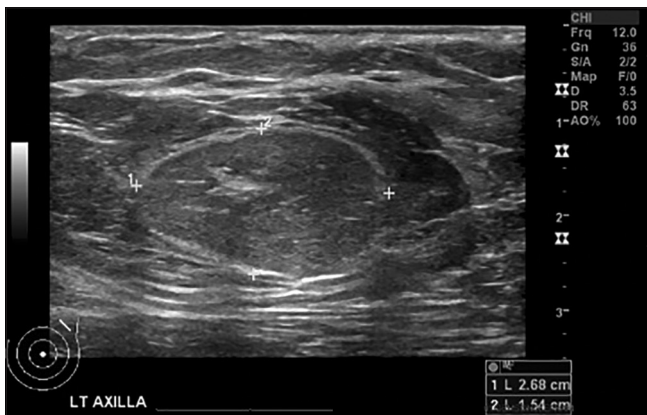

Figure 2b: A 61-year-old female who presented with left breast pain. LN with atrophic cortex and fatty infiltration of the hilum.

axillary adenopathy may be seen in lymphoma and leukemia, and HIV associated conditions, for example, Kaposi sarcoma associated immune reconstitution syndrome.

It is uncommon for axillary nodal metastases from breast cancer to be bilateral, the same is true for non-breast malignancies, lung cancer, and melanoma.^[5,6]

UNILATERAL AXILLARY ENLARGED LN

Benign causes for unilateral axillary adenopathy can be mastitis or other regional infective causes such as tuberculosis or ipsilateral arm infection, for example, cellulitis and hidradenitis.^[7] Silicone or saline implants or tissue expanders may also cause axillary adenopathy if infected.

Malignant causes for unilateral adenopathy are metastatic disease from breast cancer, melanoma, or lymphoma.

[Figure 4] (Illustration of the spectrum of abnormal lymph nodes by ultrasound).

[Figures 2a-c] (Spectrum of normal lymph node appearance).

[Figure 3] (Benign appearing and favors reactive nature).

Presence or absence of metastatic disease in the axilla is of crucial importance in breast cancer staging and treatment. With the increase incidence of early detection of breast cancer, the presence of axillary LNs metastasis has declined.

The choice of the method of obtaining a tissue sample of the sonographically suspicious LN whether it should be core or fine needle is sometimes a dilemma. In our institution, we believe that the core needle biopsy produces more accurate results. In a study performed by Balasubramanian *et al.*, they also concluded that the ultrasound core needle biopsy is a superior diagnostic technique compared to the fine-needle aspiration [FNA].^[8] As to core versus FNA, we agree with the conclusion made by Ganott *et al.* that core biopsy can be considered if the node is clearly imaged and accessible. Fine-needle aspiration should be considered (with care to obtain sufficient material) as an alternative to core biopsy in cases of difficult accessibility or when a smaller needle is desired or other patient related factors.^[9]




Figure 4: Illustration courtesy Dr. Don O’Conner, MD. Upper left image: Uniformly thickened cortex favors inflamed/reactive. Upper middle and right images: Uneven thickening or bulbous thickening of the cortex favors metastasis. Lower left: Compression of the mediastinum can be seen in metastatic or inflamed lymph node (LN). Lower middle: Absence of fatty hilum/complete nodal replacement by tumor. Lower right: Classic appearance of irregular shape/extracapsular tumoral extension.

We always found it important to use core needle biopsy for the patients undergoing a neoadjuvant chemotherapy as the identification of the FNA biopsied LN would be difficult after treatment, as compared to a LN with a metallic clip within.

Sentinel LN biopsy is shown to be similar to axillary dissection in metastatic detection with less morbidity in patients with early stage disease.^[10,11]

MORPHOLOGIC AND SIZE CRITERIA SUGGESTING METASTATIC NODES

Metastatic cells in the lymph reach the LNs through afferent lymphatic vessels located in the convex side of the LN. The lymph is then filtered through the cortex, paracortex and finally to the hilum. Metastatic deposits remain in the LN peripheral zone, causing enlargement of the cortex, usually small or focal in the beginning, or can be uniform^[1] [Figures 1 and 4].

Changes, such as cortical thickening, diminished or absent hilum, alterations in shape, or vascular pattern, are considered suspicious. Recent studies showed no significant relationship between size of LN and malignancy^[12,13] [Figures 5a-e and 6].

Stavros has also made very important points in evaluating LNs. In addition to the above parameters, he also emphasized the importance of evaluation of concentric hilar compression, convex hilar indentation “rat bite,” hilar displacement and obliteration^[14] [Figures 5a-e].

A very good parameter for evaluation of metastatic LN is the loss of the thin echogenic capsule and presence of angular margins, which suggest presence of perinodal invasion^[14] [Figure 5c].

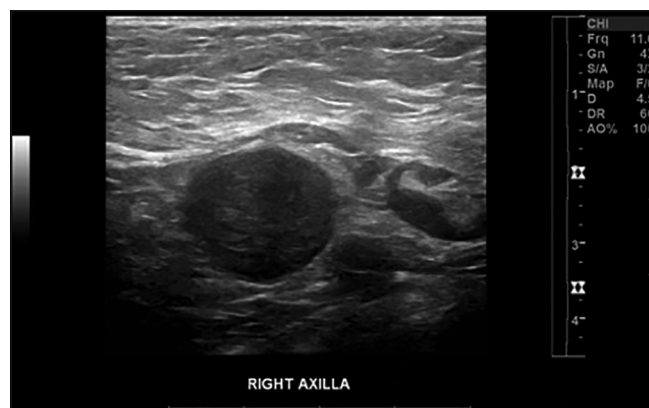

Figure 5a: A 54-year-old female with history of breast cancer. Biopsy proven metastatic reactive LN. Suspicious sign for metastasis is the presence of a normal appearing LN next to an abnormal LN with hilar loss.

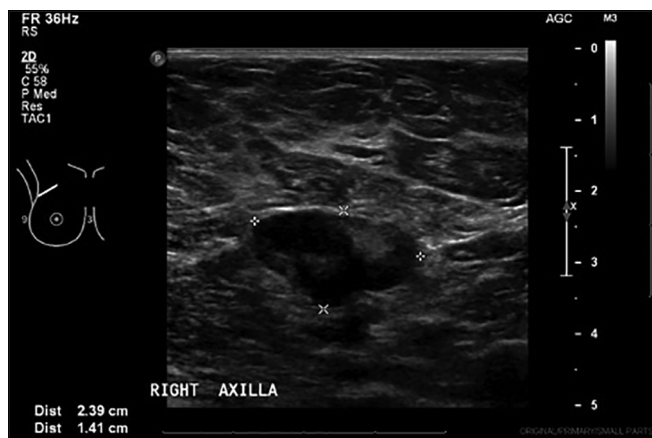

Figure 5b: A 56-year-old female with history of right breast cancer. Asymmetric cortical thickening favors metastasis. Biopsy proven metastatic LN.

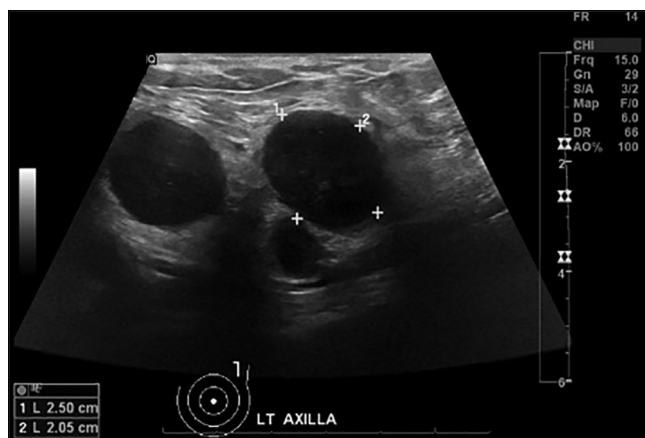


Figure 5d: Same patient of 3C. Complete mediastinal (hilar) obliteration favors metastatic infiltration.

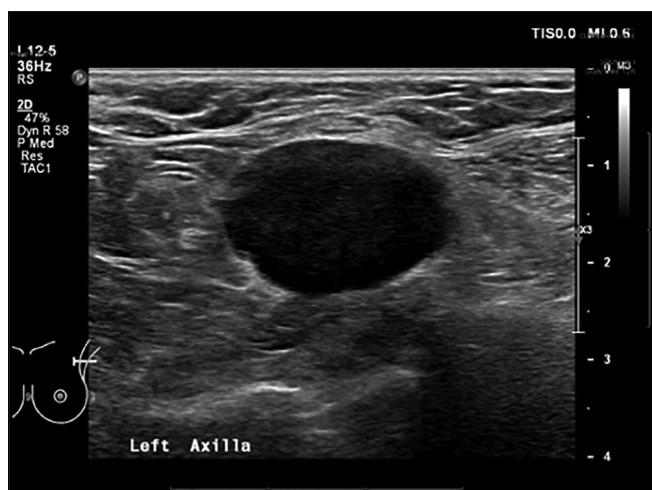


Figure 5c: A 77-year-old female with a suspicious left breast mass. Loss of normal echogenic thin cortex with fuzzy borders of the LN and some spiculations, findings favor metastasis.

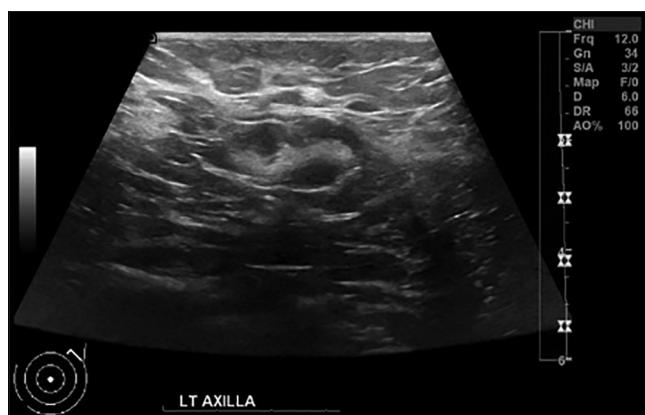

Figure 5e: A 60-year-old female with known left breast invasive ductal carcinoma. Indentation of the hilum in a biopsy proven metastatic LN (rat bite sign).

Metastasis would affect one LN at a time, so there would be an abnormal LN adjacent to a normal appearing one, unlike inflammatory reasons which tend to affect all LNs in a regional chain^[14] [Figure 5a].

At present, many studies utilize cortical thickening and hilum absence as criteria for definition of the risk for metastasis.^[12,15-17] Absence of the hilum, rendering the LN completely hypoechoic, is the most specific alteration for metastatic disease,^[12,18] but this is only seen in advanced metastasis.

The value for cortical thickness utilized as a cutoff point for metastatic disease varies in the literature, ranging from 2.3 mm to 3 mm. Some other authors use cortex/hilum ratio.^[18,19]

A classification based on the cortical thickness has been suggested by some authors. Cho *et al.*,^[15] for example,

have categorized the images into five grades: Grade 1, LNs with cortex ≤ 1.5 mm; Grade 2, > 1.5 and ≤ 2.5 mm; Grade 3, > 2.5 mm and ≤ 3.5 mm; Grade 4, > 3.5 mm; and intact hilum; Grade 5, > 3.5 mm and hilum absence. They have concluded that this classification is effective in the evaluation of metastasis and that cortical thickness > 2.5 mm (grade three) is an indication for cytological or histological study.^[11]

Bedi *et al.* developed another type of classification, six types of LNs, as follows: Type 1, without visible cortex; type 2, cortex ≤ 3 mm; type 3, cortex > 3 mm; type 4, entirely lobulated cortex; type 5, with focal lobulation; and type 6, completely hypoechoic, without hilum. LNs classified as types 5 and 6 were considered suspicious; reactive LNs were frequently observed in type 3; while type 4 was considered as probably benign, since such type comprised most false negative results.^[12]

Of the known morphologic criteria for evaluation metastatic LNs, size is the least useful unless the LN is extremely and asymmetrically enlarged.^[12]

Rounding longitudinal/transverse (L/T) ratio,^[20] Cortical/hilum (C/H) ratio.^[20] Cortical thickening >3 or 4 mm,^[15,21] Hilum effacement or loss of normal central hyperechoic hilum^[12] are all important in raising suspicion.

Performances of the CH area ratio, LT axis ratio, and blood flow pattern on power Doppler imaging for evaluation of axillary LNs.^[20] The sensitivity of the CH area ratio was superior to that of the LT axis ratio (94.1% vs. 82.3%) and to that of the blood flow pattern on the power Doppler imaging (94.1% vs. 29.4%).^[20]

Loss of echogenic thin outer cortex or angular margins can be subtle but key for suspicion.^[22,23]

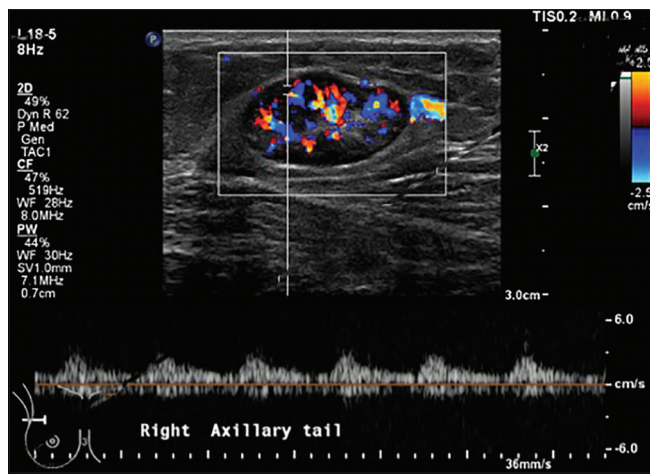


Figure 6: A 61-year-old female who presented with right breast pain and signs of infection. Biopsy proven inflammatory/reactive lymph node (LN). The vascularity is more central than peripheral, thin echogenic capsule is preserved. Pulsed Doppler shows rounded systolic peak with a relative preserved diastolic flow and the Resistive index is not high.

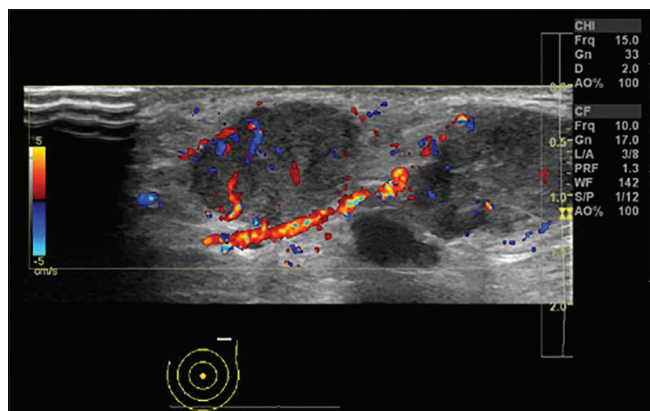


Figure 7a: A 72-year-old female with known left breast cancer. Color Doppler image of metastatic LN with transcapsular feeding vessels unlike the normal appearance of hilar vessels.

DOPPLER AND POWER DOPPLER EVALUATION OF THE AXILLARY LNs

Doppler ultrasonography, of the axillary LNs follows two patterns, central pattern, and peripheral pattern. The Peripheral vascularization is more frequently found in metastatic LNs [Figures 7a and b]. Benign inflammatory/reactive LN usually shows a more central vascularity than peripheral, thin echogenic capsule is always preserved [Figure 6].^[24]

Malignant LNs were found to have a greater total and number of peripheral vessels compared with benign axillary LNs.^[25]

Stavros has also explored the use of color Doppler in qualitative assessment of suspicious LNs. Using color Doppler has helped in assessing angiogenesis or the formation of multiple afferent vessels that feed metastatic deposits in the cortex of the LN.^[14]

CONTRAST ULTRASOUND ENHANCEMENT

Carcinoma infiltration causes new vascular formation (neovascularization) with change of the perfusion pattern with heterogeneous enhancement due to the presence of caliber changes of the neoplastic vessels and arteriovenous shunts. Malignant lymph nodes have more peripheral vessels than benign ones.^[26] They also show longer contrast enhancement duration than benign LNs. Areas of avascular necrosis (lack of contrast uptake) surrounded by hyperenhancement are another important imaging sign for malignant infiltration.

In cases of focal cortical thickening due to metastasis the cortical thickening is less well vascularized than the adjacent normal LN parenchyma compared to homogeneous enhancement in a benign LN.^[27]

In a monocentric study performed by Agliata *et al.*, They concluded that contrast-enhanced sonography of

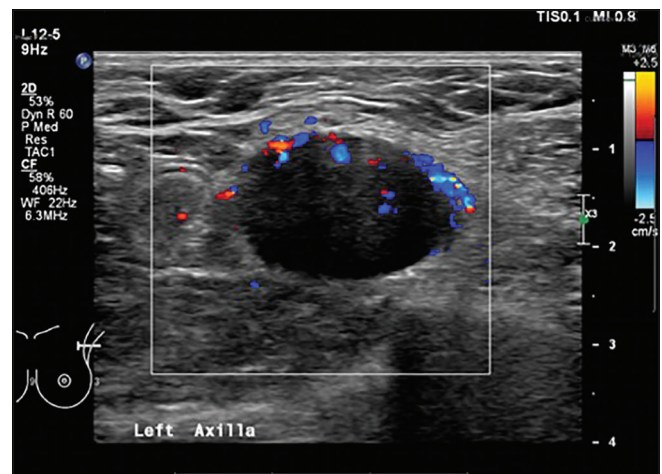


Figure 7b: A 77-year-old female with a suspicious left breast mass. Metastatic LN with increased peripheral vascularity rather than the expected normal central vascularity.

axillary LNs has high diagnostic accuracy and is superior to the traditional sonographic techniques. The sensitivity, specificity, and accuracy obtained by contrast-enhanced sonography for characterization of axillary LNs were 100%, 82%, and 92%, respectively.^[28]

SONOELASTOGRAPHY

Sonoelastography can improve the PPV as it offers a relative measurement of tissue stiffness. Cortex of metastatic LNs is stiffer than the cortex of healthy LNs [Figures 8a and b].^[29]

Ultrasound elastography provides valuable information for the differential diagnosis of benign and malignant LNs. The combination of elastography criteria with B-mode and Doppler-criteria may improve the PPV. Elastography can be useful in evaluation of metastatic areas in prominent LNs

and to find metastatic LNs in a group of enlarged LNs with a high degree of certainty.^[30]

LYMPHOMA

In the past, lymphomatous nodes were described as hypoechoic with posterior enhancement, with a pseudocystic appearance [Figure 9]. However, with the availability of the newer high resolution transducers, lymphomatous nodes demonstrate intranodal reticulation rather than the pseudocystic appearance.^[26]

Unlike metastatic nodes, lymphomatous nodes tend to have mixed vascularity and isolated peripheral vascularity is uncommon.^[26]

Lymphomatous nodes tend to be softer than metastatic nodes on elastogram.^[26]

AXILLARY LYMPHADENOPATHY AND COVID 19

During the COVID-19, pandemic a new and important cause of lymphadenopathy has emerged. A significant number of women have developed lymphadenopathy on the side of vaccine injection. The importance of knowing this is that patients with cancer should not be unnecessarily upstaged, and women without cancer should not be worked up for ipsilateral lymphadenopathy as a possible sign of occult breast cancer. Current guidelines endorsed by the Society of Breast Imaging (SBI) suggest a short-term ultrasound follow up 2–3 months after the second dose if two doses are given.^[31]

CONCLUSION

LN evaluation at the time of diagnosis of breast cancer is critical to appropriate management, either with surgery first

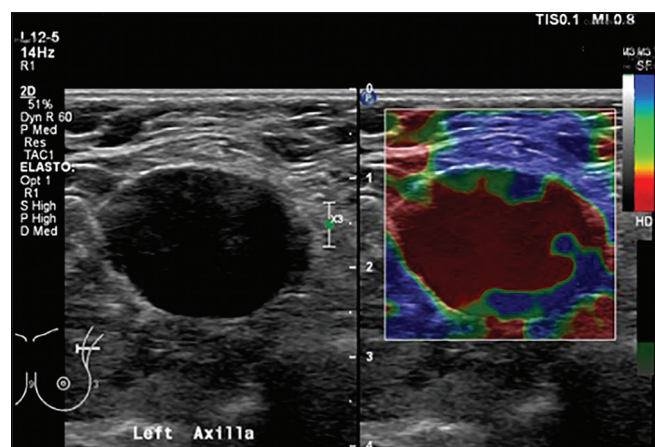


Figure 8a: A 77-year-old female with history of the left breast cancer. Biopsy proven metastatic LN with diffuse increased stiffness and lost normal echogenic hilum.

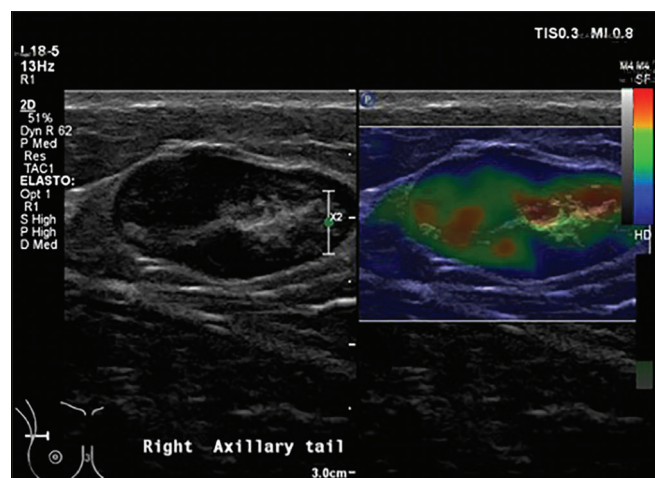


Figure 8b: A 61-year-old female who presented with right breast pain and signs of infection. Biopsy proven inflammatory/reactive LN. Benign lymph node with fatty hilum and no evidence of increased stiffness.

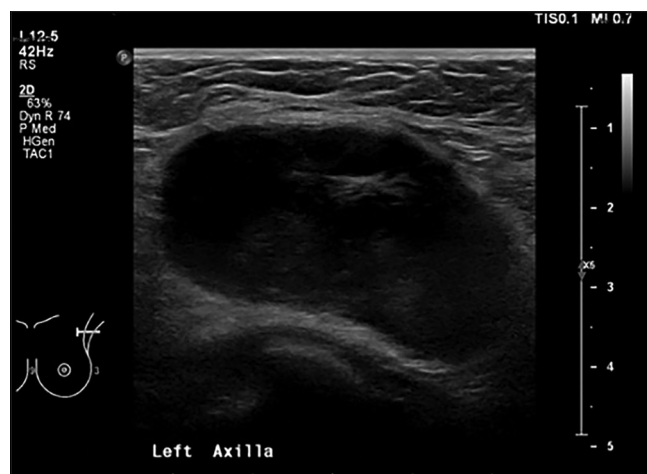

Figure 9: A 41-year-old female with history of lymphoma presents with lump in the left axilla. Biopsy proven lymphoma with increased through transmission and intranodal reticulation.

or neoadjuvant chemotherapy whichever is indicated. Breast imaging and appropriate biopsy of axillary LNs is crucial in providing optimal care and minimizing morbidity due to unnecessary axillary surgery. For this reason, dedicated breast imagers must understand the abnormal features of involved LNs and be comfortable in providing safe sampling under ultrasound guidance. Morphologic criteria to know suggesting metastatic involvement include thickened, irregular or bulging cortex, rounding, and asymmetric hilar loss. Variability in cortical thickening in different nodes within the same axilla also favors metastasis. Transcortical vessels are abnormal and strongly suggest metastasis. Use of combined B-mode and sonoelastogram criteria of malignancy improves the specificity of ultrasound in detection of malignant LNs. This knowledge is essential for optimal care.

Unilateral axillary lymphadenopathy is currently more common than ever secondary to COVID vaccination. This should be followed with special attention to the current exceptional circumstances, and following SBI guidelines is important.

Declaration of patient consent

Patient's consent not required as patients identity is not disclosed or compromised.

Financial support and sponsorship

Nil.

Conflicts of interest

There are no conflicts of interest.

REFERENCES

1. Pinheiro DJ, Elias S, Nazário AC. Axillary lymph nodes in breast cancer patients: Sonographic evaluation. *Radiol Bras* 2014;47:240-4.
2. Walsh R, Kornguth PJ, Soo MS, Bentley R, DeLong DM. Axillary lymph nodes: Mammographic, pathologic, and clinical correlation. *AJR Am J Roentgenol* 1997;168:33-8.
3. Godoy MC, Rouse H, Brown JA, Phillips P, Forrest DM, Müller NL. Imaging features of pulmonary kaposi sarcoma-associated immune reconstitution syndrome. *AJR Am J Roentgenol* 2007;189:956-65.
4. Christiaensen E, Jacquemyn Y, Verslegers I, van Goethem M, van Marck V. Axillary lymphadenopathy as a first symptom of diabetic mastopathy. *BMJ Case Rep* 2009;2009. Doi: 10.1136/bcr.03.2009.1703.
5. Cardenosa G. *Clinical Breast Imaging: A Patient Focused Teaching File*. Philadelphia, PA: Lippincott Williams & Wilkins; 2006.
6. Youk JH, Kim EK, Ko KH, Kim MJ. Sonographic features of axillary lymphadenopathy caused by Kikuchi disease. *J Ultrasound Med* 2008;27:847-53.
7. Shetty MK, Carpenter WS. Sonographic evaluation of isolated abnormal axillary lymph nodes identified on mammograms. *J Ultrasound Med* 2004;23:63-71.
8. Balasubramanian I, Fleming CA, Corrigan MA, Redmond HP, Kerin MJ, Lowery AJ. Meta-analysis of the diagnostic accuracy of ultrasound-guided fine-needle aspiration and core needle biopsy in diagnosing axillary lymph node metastasis. *Br J Surg* 2018;105:1244-53.
9. Ganott MA, Zuley ML, Abrams GS, Lu AH, Kelly AE, Sumkin JH, *et al.* Ultrasound guided core biopsy versus fine needle aspiration for evaluation of axillary lymphadenopathy in patients with breast cancer. *ISRN Oncol* 2014;2014:703160.
10. Krag DN, Weaver DL, Alex JC, Fairbank JT. Surgical resection and radiolocalization of the sentinel lymph node in breast cancer using a gamma probe. *Surg Oncol* 1993;2:335-9; discussion 340.
11. Kell MR, Burke JP, Barry M, Morrow M. Outcome of axillary staging in early breast cancer: A meta-analysis. *Breast Cancer Res Treat* 2010;120:441-7.
12. Bedi DG, Krishnamurthy R, Krishnamurthy S, Edeiken BS, Le-Petross H, Fornage BD, *et al.* Cortical morphologic features of axillary lymph nodes as a predictor of metastasis in breast cancer: *In vitro* sonographic study. *AJR Am J Roentgenol* 2008;191:646-52.
13. Koelliker SL, Chung MA, Mainiero MB, Steinhoff MM, Cady B. Axillary lymph nodes: US-guided fine-needle aspiration for initial staging of breast cancer-correlation with primary tumor size. *Radiology* 2008;246:81-9.
14. Stavros A, Rapp C, Parker S. Evaluation of Regional Lymph Nodes in Breast Cancer Patients in Breast Ultrasound. Philadelphia, PA: Lippincott Williams & Wilkins; 2004. p. 834-76.
15. Cho N, Moon WK, Han W, Park IA, Cho J, Noh DY. Preoperative sonographic classification of axillary lymph nodes in patients with breast cancer: Node-to-node correlation with surgical histology and sentinel node biopsy results. *AJR Am J Roentgenol* 2009;193:1731-7.
16. Moore A, Hester M, Nam MW, Brill YM, McGrath P, Wright H, *et al.* Distinct lymph nodal sonographic characteristics in breast cancer patients at high risk for axillary metastases correlate with the final axillary stage. *Br J Radiol* 2008;81:630-6.
17. Mainiero MB, Cinelli CM, Koelliker SL, Graves TA, Chung MA. Axillary ultrasound and fine-needle aspiration in the preoperative evaluation of the breast cancer patient: An algorithm based on tumor size and lymph node appearance. *AJR Am J Roentgenol* 2010;195:1261-7.
18. Abe H, Schmidt RA, Kulkarni K, Sennett CA, Mueller JS, Newstead GM. Axillary lymph nodes suspicious for breast cancer metastasis: Sampling with US-guided 14-gauge core-needle biopsy--clinical experience in 100 patients. *Radiology* 2009;250:41-9.
19. Luparia A, Campanino P, Cotti R, Lucarelli D, Durando M, Mariscotti G, *et al.* Role of axillary ultrasound in the preoperative diagnosis of lymph node metastases in patients affected by breast carcinoma. *Radiol Med* 2010;115:225-37.
20. Song SE, Seo BK, Lee SH, Yie A, Lee KY, Cho KR, *et al.*

- Classification of metastatic versus non-metastatic axillary nodes in breast cancer patients: Value of cortex-hilum area ratio with ultrasound. *J Breast Cancer* 2012;15:65-70.
21. Saffar B, Bennett M, Metcalf C, Burrows S. Retrospective preoperative assessment of the axillary lymph nodes in patients with breast cancer and literature review. *Clin Radiol* 2015;70:954-9.
 22. Clark DA. Preoperative ultrasound of axillary lymph nodes in patients with breast cancer. *ANZ J Surg* 2008;78:307-8.
 23. Busilacchi P, Draghi F, Preda L, Ferranti C. Has color Doppler a role in the evaluation of mammary lesions? *J Ultrasound* 2012;15:93-8.
 24. Yang WT, Chang J, Metreweli C. Patients with breast cancer: Differences in color Doppler flow and gray-scale US features of benign and malignant axillary lymph nodes. *Radiology* 2000;215:568-73.
 25. Yang WT, Metreweli C, Lam PK, Chang J. Benign and malignant breast masses and axillary nodes: Evaluation with echo-enhanced color power Doppler US. *Radiology* 2001;220:795-802.
 26. Ying M, Bhatia KS, Lee YP, Yuen HY, Ahuja AT. Review of ultrasonography of malignant neck nodes: Greyscale, doppler, contrast enhancement and elastography. *Cancer Imaging* 2014;13:658-69.
 27. Cui XW, Jenssen C, Saftoiu A, Ignee A, Dietrich CF. New ultrasound techniques for lymph node evaluation. *World J Gastroenterol* 2013;19:4850-60.
 28. Agliata G, Valeri G, Argalia G, Tarabelli E, Giuseppetti GM. Role of contrast-enhanced sonography in the evaluation of axillary lymph nodes in breast carcinoma: A monocentric study. *J Ultrasound Med* 2017;36:505-11.
 29. Wojcinski S, Dupont J, Schmidt W, Cassel M, Hillemanns P. Real-time ultrasound elastography in 180 axillary lymph nodes: Elasticity distribution in healthy lymph nodes and prediction of breast cancer metastases. *BMC Med Imaging* 2012;12:35.
 30. Chiorean L, Barr RG, Braden B, Jenssen C, Cui XW, Hocke M, *et al.* Transcutaneous ultrasound: Elastographic lymph node evaluation. Current clinical applications and literature review. *Ultrasound Med Biol* 2016;42:16-30.
 31. Available from: <https://www.sbi-online.org/portals/0/position%20statements/2021/sbi-recommendations-for-managing-axillary-adenopathy-post-covid-vaccination.pdf>. [Last accessed on 2021 Feb 01].

How to cite this article: Hussien AR, El-Quadi M, Oconnell A. Value of Ultrasound in Evaluation of Abnormal Axillary Lymph Node. *Am J Sonogr* 2021;4:3.